



TRUE EYE EMERGENCIES

Dewanti Widya Astari*, Patriotika Muslima, Putri Utami, Kreati Hanna Putri, Ilham Rohmat

Febrian, Amanda Widayanti, Saraya Amajida, Diaz Hazrina Setiadi, Efi Octaviany

Cicendo Eye Hospital, Jl. Cicendo No.4, Babakan Ciamis, Bandung Well, Bandung, West Java 40117, Indonesia

*dewantiwidya@gmail.com

ABSTRACT

Eye emergency is an eye emergency where a condition requires immediate medical attention due to sudden changes in eye health or vision. This case series aims to determine various cases of eye emergencies. The method used is a descriptive case series report design based on true eye emergency case in tertiary referral hospital. The sampling technique used was accidental sampling with the respondents being emergency department patients, totaling 8 respondents. Data was obtained by observation, interviews and participant observation. Management is traced from anamnesis to evaluation. The eye emergencies cases included are chemical trauma, penetrating trauma, endophthalmitis, acute attack glaucoma, open trauma of the eyeball, central retinal artery occlusion, corpus alienum, and mechanical trauma. Handling eye emergencies focuses on precision, accuracy and response time.

Keywords: eye emergencies; ophthalmology; trauma

First Received

10 December 2023

Revised

18 December 2023

Accepted

30 December 2023

Final Proof Received

08 February 2024

Published

12 February 2024

How to cite (in APA style)

Astari, D., Muslima, P., Utami, P., Putri, K. H., Febrian, I. R., Widayanti, A., Amajida, S., Setiadi, D. H., & Octaviany, E. (2024). True Eye Emergencies. *Indonesian Journal of Global Health Research*, 6(1), 279-298. <https://doi.org/10.37287/ijghr.v6i1.2695>.

INTRODUCTION

Eye emergency is an eye emergency where a condition requires immediate medical attention due to sudden changes in eye health or vision.^(Brit Long & Alex Koyfman, 2018) The eye emergencies cases included are chemical trauma, eyeball trauma, endophthalmitis, acute attack glaucoma, optic neuritis, orbital cellulitis, globe prolapse, optic neuropathy due to methanol, blackball hyphema, secondary glaucoma due to anterior luxation of the lens, central retinal artery occlusion, intraocular foreign bodies, macular retinal detachment, acute submacular hemorrhage, penetrating eyeball trauma and gonorrhoeae conjunctivitis. The aim of this case series is to describe cases of true eye emergencies that rarely occur.

METHOD

The method used is a descriptive case report design by focusing on efforts to true eye emergencies. The subjects in this scientific work are eight patients in emergency unit tertiary referral hospital. The sampling technique used was accidental sampling with the respondents being emergency department patients, totaling eight respondents. Data was obtained by observation, interviews and participant observation. Management is traced from anamnesis to evaluation. A case series describing the clinical manifestations, course of the condition and prognosis of the cases.

RESULTS

Eye emergencies are often situations that require immediate treatment to prevent permanent damage to vision. The causes of eye emergencies can vary, including trauma, infection, inflammation or other serious eye disease. A series of eye emergency cases includes the following 8 eye emergency cases:

Case 1: Open trauma of the eyeball

Case scenario

A 40 year old man came with complaints of acute pain in the right eye, redness, accompanied by a sharp decrease in vision due to a collision between the bicycle he was riding and a motorbike. The patient fainted and regained consciousness while in the hospital. Visual acuity in the right eye is 1/300 and the left eye is 1.0. Examination showed that there was a vulnus laceratum from limbus to limbus accompanied by vitreous prolapse.

Background

Open traumatic mechanical injury to the eyeball occurs as a result of full-thickness rupture or laceration of the cornea or sclera. Eyeball rupture occurs after a blunt force injury to the eye due to trauma such as a ball throw, air sac injury, or attack. Eyeball lacerations occur following trauma from penetrating objects (e.g. knives, high-velocity projectiles). The annual incidence of open mechanical eyeball trauma is 3.8 per 100,000 people, with most injuries occurring at work or during recreational activities.(Mayer, Reznicek, Baur, & Khoramnia, 2021). Open trauma to the eyeball is classified as type A, namely rupture; type B, namely penetrating; type C, namely intraocular foreign body; type D is perforating and type E is mixed. The level of severity (grading) is based on visual acuity, namely Grade A visual acuity $\geq 20/40$, Grade B visual acuity 20/50 to 20/100; Grade C visual acuity 19/100 to 5/200; Grade D visual acuity 4/200 to light perception; and Grade E has no light perception.(Seanna Grob & Kloek, 2018).

Diagnosis

Open trauma to the eyeball is damage to the entire thickness of the eye wall and is often differentiated based on the mechanism of injury that causes it: sharp or blunt trauma. This is an ocular emergency and can cause major visual morbidity. Without timely intervention, the damage cannot be repaired and leads to permanent vision loss. In this review, best practices for evaluation and management are reviewed, with a particular focus on surgical approaches and techniques.(Zhou, DiSclafani, Jeang, & Shah, 2022). Patients with mechanical eyeball injuries will experience eye pain, redness, tearing, or decreased vision immediately after trauma to the eye. Examination of the anterior segment with a slit lamp or flashlight can identify injuries to the eyeball. Clinical features may include subconjunctival hemorrhage, pupil irregularity, and iris prolapse through a corneal or scleral wound. If a foreign object is visible and protruding from the eyeball, it should not be removed. Pharmacological pupil dilation and intraocular pressure measurement are not recommended. Wet fluorescein dye strips can be applied near the site of a possible rupture or laceration for examination under cobalt blue light. The presence of fluorescein-stained water flowing from the eye indicates injury to the eyeball. Computed tomography of the orbit can evaluate for intraocular foreign bodies or orbital wall fractures.

Treatment

Intervention must initiated to prevent increased intraocular pressure if an ocular injury is diagnosed or suspected. Patients should be instructed to prevent valsalva maneuvers, including coughing or straining, and to avoid external pressure on the eye to prevent extrusion

of intraocular contents. A metal shield should be placed over the eye, and the patient should be referred immediately to an ophthalmologist.

Posttraumatic endophthalmitis, commonly caused by bacillus, streptococcus, and coagulase-negative staphylococcus species, may occur in up to 8% of cases when there is an associated intraocular foreign body. Prophylactic systemic antibiotics are recommended to reduce the risk of endophthalmitis following globe rupture or mechanical laceration. Levofloxacin is an appropriate first-line treatment. Antifungal therapy with voriconazole or fluconazole may be considered if plants or organic materials are the cause. Tetanus toxoid, reduced diphtheria toxoid, and acellular pertussis vaccine (Tdap) booster should also be given. Surgical management of eyeball injuries and removal of intraocular foreign bodies reduces the risk of endophthalmitis if surgery is performed within 24 hours after injury. Therefore, patients who are suspected of having an eyeball injury should be immediately referred to an ophthalmologist.

Prognosis

Debridement is carried out on the eye area where there is an open wound. However, the wound healing process in eye tissue shows similar characteristics to other tissues. The main principle of general surgery is to remove contaminated or infectious necrotic tissue. However, intraocular debridement differs from other tissue after injury because the intraocular tissue is not infected. In contrast, intraocular debridement aims to eliminate the causes of persistent inflammation and abnormal proliferation (Langan, 2022). Follow-up after ocular injury should include monitoring of systemic conditions and sympathetic ophthalmia. Timely evaluation and treatment is necessary to reduce visual morbidity. Analgesics, antibiotics, and eye protection are necessary to limit intraocular pressure (IOP), prevent infection, and prevent further injury. Adequate surgical exploration is required throughout the injured eyeball. Suture technique is very important to achieve optimal results. After primary repair, IOP control and antibiotics are also necessary, followed by secondary repair and close evaluation.

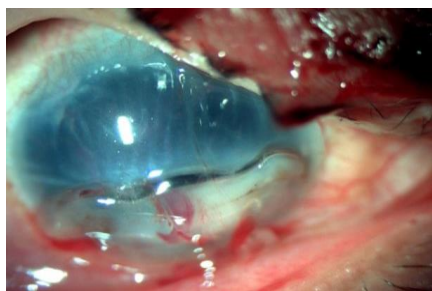


Figure 1. Front view shows a laceration of the vulnus from limbus to limbus accompanied by vitreous prolapse.

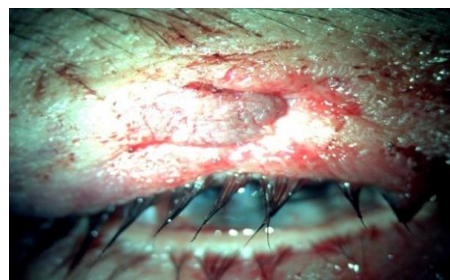

Figure 2. Shows the wound laceration in the superior palpebral area.

Case 2: Chemical Trauma

Case Scenario

A 23 year old man came to the hospital with complaints of sore, red, watery eyes, discomfort in the eyes, because he was splashed with toilet cleaning fluid approximately 5 hours ago before entering the hospital. Visual acuity in the right eye is 0.16 pH 0.63 and the left eye is 0.2 pH 0.5. Examination showed abrasion of the cornea of the right and left eye. The conjunctiva showed ciliary injection, hyperemia with Potention Hydrogen (pH) in the right and left eye 7. Physical examination showed that the patient appeared moderately ill, was conscious, blood pressure 156/97 mmHg, pulse 84 times per minute, respiration 18 times per minute and temperature 36.3C. There is no loss of supercilia, good eye movement in all

directions, there is edema in the superior and inferior eyelids, sclera is icteric (-), cornea has no erosion and ischemia in the lateral temporal limbus, synechiae of the iris (-), round pupil measuring 3 mm, central regular, light reflex (+), clear lens, fundus reflex (+), NCT (non contact tonometry) OD: 17 mmHg, OS: 15 mmHg.

Background

Chemical trauma to the eye is an ophthalmological emergency because it can cause injury to the eye, whether mild or severe, and even loss of vision. Chemical trauma to the eye is trauma that affects the eyeball due to exposure to chemicals, either acidic or alkaline, which can damage the structure of the eyeball. Chemical trauma usually occurs in trauma to the cornea and conjunctiva caused by contact with chemicals, resulting in decreased vision and visual field abnormalities. Chemical trauma by acid solutions will mostly only affect the epithelial boundaries of the eye, but if it penetrates deeper into the stroma it can harm vision. Chemical trauma caused by strong acids makes the corneal stroma turn gray so that inflammatory cells infiltrate into it. Infiltration of inflammatory cells into the stroma by acidic substances occurs within 24 hours.

Treatment

The main goal of therapy is to suppress inflammation, pain, and the risk of inflammation. The emergency treatment given is: Eye irrigation, preferably using normal saline or Ringer's lactate solution for at least 30 minutes. If only non-sterile water is available, then that water can be used. Non-pharmacological management of eye irrigation with 0.9% NaCl 4-5 kolf with superior eyelid eversion technique until the litmus paper test reaches neutral pH. Do this ten minutes / 30-60 minutes after the irrigation has stopped, measure the pH using litmus paper. Irrigation is continued until it reaches neutral pH (pH=7.0). If the pH remains high, the fornix conjunctiva is swabbed using a moistened cotton-tipped applicator. (Fogt, Jones-Jordan, & Barr, 2018).

Treatment for mild to moderate degree chemical trauma is the fornix swabbed using moistened cotton-tipped, cycloplegic medication (scopolamine 0.25%; atropine 1%), broad spectrum topical antibiotics as prophylaxis for infection. Oral analgesics, such as acetaminophen, can be given to treat pain. If there is an increase in intraocular pressure > 30 mmHg, acetazolamide (4x250 mg or 2x500 mg orally), beta blockers (timolol 0.5% or levobunolol 0.5%), water can be given. artificial eyes (if no pressure patch is applied). Management for severe chemical trauma after irrigation includes referral to hospital for intensive monitoring of intraocular pressure and corneal healing, debridement of necrotic tissue containing foreign material, cycloplegic (scopolamine 0.25%; atropine 1%) given 3- 4 times a day. Topical antibiotics (trimethoprim or polymixin-polytrim 4 times a day, erythromycin 2-4 times a day), topical steroids (prednisolone acetate 1%; dexametasone 0.1% 4-9 times a day). Steroids can reduce inflammation and neutrophil infiltration which inhibits reepithelialization. It should only be used for the first 7-10 days because if it takes longer it can inhibit collagen synthesis and fibroblast migration so that the healing process is hampered.

Prognosis

Spooling (irrigation) of the eye using the palpebral eversion technique with the aim of removing material that causes chemical trauma is carried out as cleanly as possible. The irrigation given should be carried out for 60 minutes, then a litmus paper test is carried out, irrigation is stopped when the pH is neutral. Initial medical therapy aims to immediately reepithelialize and transdifferentiate the surface of the eyeball, accelerate corneal healing by

helping the production of keratocytes and collagen and reducing inflammation.(Chen et al., 2017) The antibiotics that can be given are fourth generation fluoroquinolone antibiotics, one of which is moxifloxacin, which is useful for preventing infections by opportunistic germs. Inflammation through several mechanisms, including direct inhibition of active matrix metalloproteinase which degrades collagen, inhibition of oxidative activation of pro-matrix metalloproteinase, reduction of cytokine and prostaglandin synthase secretion, as well as increasing pro-anabolic production. Administration of chelating agents as collagenase inhibitors helps the process. wound healing by inhibiting collagenolytic activity and thereby preventing stromal ulceration. Some collagenase inhibitors include cysteine, acetylcysteine, sodium ethylene diamine tetra acetate (EDTA), calcium EDTA, vitamin C with the aim of increasing collagen production and having the advantage of being able to suppress corneal perforation. After the patient has been given corticosteroids and antibiotics drops or topicals, a pressure patch can be given with the aim of preventing infection. After initial therapy and irrigation, the patient must be closely observed to see the possibility of injury sequelae such as corneal ulceration, dry eyes, malposition from the eyelids due to scars. Timely evaluation and treatment are needed to reduce visual morbidity and mortality.

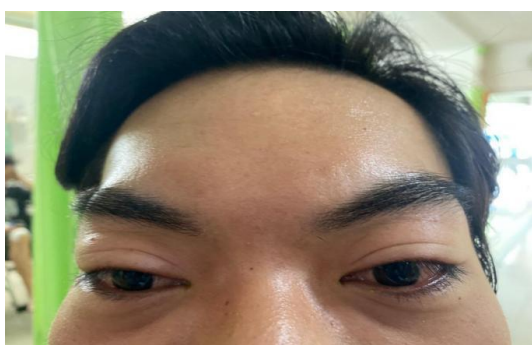

Figure 3. front view shows the conjunctiva of both eyes and ciliary injection hyperemic

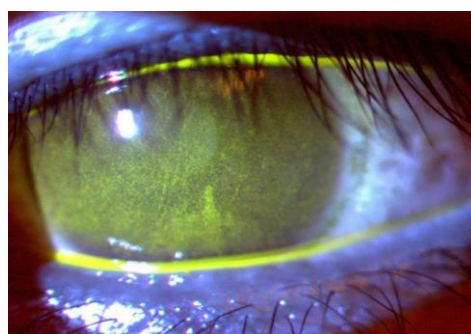


Figure 4. shows a corneal abrasion seen using fluorescence staining with cobalt blue filter light during a slit lamp examination

Case 3: Penetrating Trauma

Case Scenario

A 17 year old child came to the Vertical Hospital Emergency Department with complaints of acute pain in the left eye, penetrating wounds, bleeding, accompanied by a sharp decrease in vision due to being shot by an air soft gun by his friend 2 hours before entering the hospital. The patient was initially sitting chatting with friends, suddenly there was a riot and there were shots from unknown directions by people he didn't know. The patient did not realize the direction of the shot and only realized when the eye was bleeding. The patient feels as if something has entered the eye and is not coming out again. After the incident, his left eye suddenly became blurry and blood and fluid came out of his eye. At the time of the incident the patient was drunk after drinking alcohol. complaints accompanied by headaches, no nausea, no vomiting, no history of fainting, no seizures, no nose, ear and mouth bleeding. The left eye had been bandaged before the child was taken by a friend to the regional hospital and to the general vertical hospital and then referred to the special eye vertical hospital. Right eye visual acuity 0.8 pin hole 1.0 and left eye Light Perception (LP) with poor projection. Examination showed that movement of the left eyeball was difficult to assess, blepharospasm on the superior and inferior lids, chemosis, full thickness vulnus laceratum measuring > 10 mm, vitreous gel on the lip of the wound, corneal edema, hyphema in the anterior chamber of the eye (black ball).

Background

Eye trauma is the leading cause of monocular blindness worldwide, and more than 55 million cases are reported each year, of which 1.6 million result in vision loss. Approximately 200,000 cases of eye trauma are open globe injuries. Open globe injuries include penetrating eye injuries, perforating eye injuries, eye rupture, and intraocular foreign bodies and can cause severe damage to intraocular tissue and vision. In the younger generation, more than one third of open globe injuries were found to be work-related, and 89.1% of these patients did not wear adequate eye protection. In addition, children are at high risk of eye injury. According to previous reports, eye injuries in children occur from 6 months to 14 years of age and are more common in boys. Home is the most common place where accidents occur and most injuries are caused by sharp objects such as knives. Particular attention should be paid to preventing eye injuries in jobs that are prone to eye trauma.

Diagnosis

Penetrating trauma to the eye is an injury to the eye caused by a sharp object that punctures or penetrates the tissue in the eye resulting in damage to all or part of the eye organ. Eye injury due to penetrating trauma is an eye emergency and can cause loss of visual function. Prevention of vision loss due to eye injuries due to penetrating trauma requires early diagnosis and immediate treatment including good primary first aid and immediate referral to a special eye care facility. Laceration refers to an open globe injury caused by sharp trauma, namely an object cutting or piercing the eye. Although a laceration is called penetrating trauma, any mechanism that penetrates the eye directly, such as a gunshot, is also called a laceration. Lacerations can be further classified as penetrating, perforating, mixed, or intraocular foreign bodies (IOFB) injuries. Perforating injuries relate to both entry and exit wounds, while penetrating injuries refer to wounds with no exit. If the incoming object remains in the eye, it is called an intraocular foreign body (IOFB).

In cases of eye injury due to penetrating bullet trauma, the manifestations that will appear are pain in the eye, bleeding, swelling in part or all of the eye, torn and penetrating wounds in the eye, a significant decrease in visual acuity and a decrease or increase in eye pressure caused by bleeding. A physical examination of the eyes is required, including visual acuity examination, pupillary reflex examination, direct visualization using a slit lamp or flashlight and even a funduscopy if possible. any pressure on the eye should be avoided, as it can dislodge intraocular contents. If signs of open globe injury are found on examination, then preparation for surgery should be made as further examination is carried out.

In cases of large anterior open globe injuries, changes in shape can be clearly seen on inspection with a flashlight. Small lacerations can also be identified with the Seidel test, where the eye is dripped with topical anesthetic, then fluorescein and illuminated with cobalt blue light or a Wood's lamp. Other examinations such as eye movement, confrontation visual field test, color test can be postponed if the clinical examination shows an open globe injury or after exploration has been carried out in the operating room. Intraocular pressure measurement is contraindicated in suspected open globe injury.

Supporting examinations can be carried out immediately after the initial study is complete, such as radiological examinations (head x-rays in various positions), ultrasound, and other examinations that can be carried out to determine the condition of the eyeball. With this examination, it is hoped that it can identify whether there is a foreign object in the eyeball (bullet) as well as the distribution of foreign object fragments that have entered the eye. Ultrasound examination is contra-indicated if the eye is experiencing a decrease in pressure due to an open wound. If this examination is necessary, attention must be paid, especially not

to put pressure on the eyeball when the examination is carried out. Other examinations such as B scan ultrasound provide some advantages over CT scans but are not recommended for confirmed cases of open globe injury. Ultrasonography also has high resolution for posterior injuries compared with CT scan and has high specificity (100%) for retinal detachment and foreign bodies.

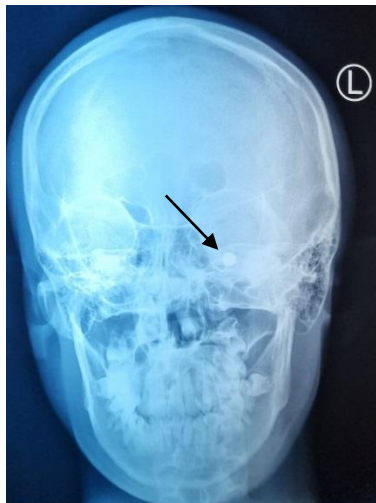

Figure 5. Schedel Ap Lateral, an image of a bullet lodged in the left eyeball was found

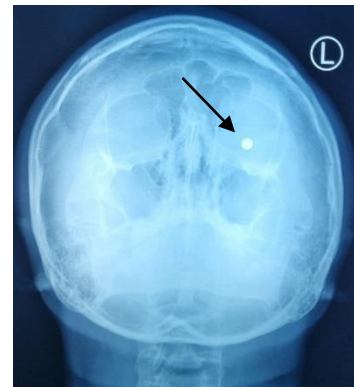
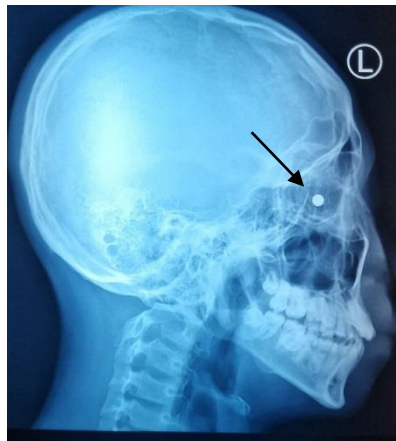
Figure 6. Waters

Treatment

Procedures for handling cases of penetrating trauma due to bullet shots must be carried out immediately simultaneously with a thorough examination in order to obtain accurate data without causing complications as a result of the examination process. Patients are advised to fast (empty the stomach) until a diagnosis is made, this aims to prepare for surgery if it is carried out immediately. Controlling bleeding and carrying out aseptic examinations is necessary to prevent complications that can lead to infection in all or part of the eye. Bandaging the eye is an important concern in stopping bleeding early, but avoid excessive pressure on the eye, gauze filled with blood must be replaced without removing the underlying gauze so that the source of bleeding in the wound does not reopen. Each gauze change must be counted to see the amount of blood loss. Administration of anti-tetanus serum and tetanus toxoid is recommended to prevent infection due to tetanus. Surgical procedures in tertiary hospitals must be carried out immediately, every preparation for surgery is carried out immediately. Supporting preparations for patients are carried out quickly, consultation regarding preparations for surgery with related units is necessary, such as preparation for anesthesia and the operating team is immediately prepared.

Prognosis

Informed consent post-operative visual prognosis and the purpose of the procedure is not for vision must be carried out, considering the serious trauma condition. Vision will decrease or even disappear depending on a number of factors, such as the degree of damage from the eye injury, how quickly medical treatment is given, and the patient's condition. Several factors that influence the prognosis of an open globe injury are: Size and Location of the Wound: The size and location of the injury to the eye can greatly influence the prognosis. Small, superficial injuries to the eye may have a better prognosis than injuries that are deep or involve the central part of the eye. Treatment Time: Speed in obtaining appropriate medical treatment is critical. The sooner medical action is taken, the better the prognosis. Infection: The risk of infection is a serious complication that can occur with open globe injury.

Prophylactic antibiotics and sterile care can help reduce the risk of infection. Additional Injuries: The presence of additional injuries to the eye or surrounding structures, such as the lens or retina, can significantly affect the prognosis. Age and General Health of the Patient: The general health of the patient and age can also influence the prognosis. Younger and healthier patients may have a better chance of cure. Patient's Ability to Comply: Patient compliance with care and treatment instructions also plays a role in prognosis. It is important to follow your doctor's directions carefully.

Eye surgery aims to remove foreign objects, close wounds, remove and stop bleeding in the eye organs, thereby preventing infection in the eye. Further examination after surgery, such as an ultrasound examination, is needed to monitor the condition of the eye for inflammation or infection, as well as evaluating the condition of the posterior eye. Providing education about wound care, administering topical and oral medications, good nutrition and scheduling follow-up visits is necessary to avoid unexpected complications.

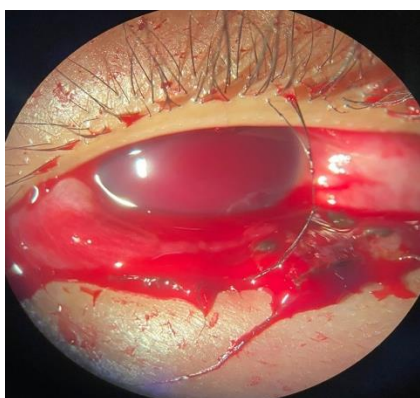


Figure 7. Condition of the anterior left eye, visible hyphema (black ball) and VL in the bulbar conjunctiva with bleeding and edema.

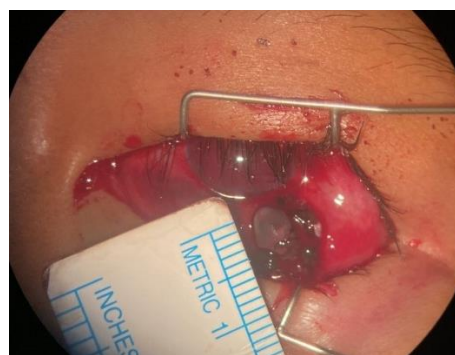

Figure 8. Exploration was carried out to determine the extent of the wound, visible vitreous gel on the lip of the wound

Case 4: Acute Glaucoma

Case Scenario

A 50 year old woman came to the emergency room at Cicendo Eye Hospital with complaints of pain in the right eye, pain felt all the way to the head, complaints of nausea but not vomiting. Patients with a history of glaucoma have not been controlled for 1 year. Intra-ocular pressure on palpation of the right eye was n+, using Goldmann applanation tonometry, the results were 60mmHg. Right eye vision obtained Light Perception. Examination revealed corneal edema with shallow COA.

Background

Primary Angle Closure Glaucoma (PACG) is an anatomical abnormality resulting in occlusion of the iridocorneal angle by the peripheral iris. This can occur between the peripheral iris and the trabecular meshwork or with the peripheral cornea. This can be reversible or permanent due to the presence of synechiae. The peripheral iris is pulled forward (anterior mechanism) or can be pushed forward (posterior mechanism). Several factors that may be risk factors for PACG include shallow anterior chamber, narrow iris corneal angle, and age.(Academy of Ophthalmology, 2019). The most common mechanism for PACG is that there is an obstruction to the outflow of aqueous humor from the rear chamber to the anterior chamber. This is called pupillary block. Mid-dilation of the pupil causes pupillary block and relaxation of the peripheral iris causes the iris root to close the iris-corneal angle. Mid-dilated

pupils can occur due to fatigue, emotions, fear, stress, or use of mydriatic medications. Several mechanical factors associated with pupillary block include: lens position that is too forward, pupil dilation/constriction, iris elasticity, iris thickness, lens thickness, zonular elasticity, and changes in the ciliary body. The clinical picture that occurs in PACG is very dependent on the extent and speed of the corner closure process. If it occurs suddenly and widely, you will get a picture of an acute attack.(Braunger, Fuchshofer, & Tamm, 2015).

Acute Primary Angle Closure Glaucoma, has typical complaints. This glaucoma attack is caused by a rapid increase in intraocular pressure due to a sudden block of the trabecular meshwork by a large iris. This complaint occurs seriously and suddenly. Manifestations that occur usually include blurred vision, rainbow-colored halos around lights, eye pain, headaches of varying degrees, nausea and vomiting. The prevalence of acute angle closure attacks is unilateral, 5% to 10% occur bilaterally. A significant increase in intraocular pressure is the main symptom. The most accurate examination uses an applanation tonometer from Goldmann. Expansion of ocular tissue, including the cornea, iris and entire eyeball, causes pain in the eyeball. Corneal endothelial function is impaired as a result of intraocular enhancement. This causes corneal edema with stretching of the stromal layer. The patient's complaint is blurred vision and visible halos around light, with the central halo being greenish blue and the peripheral halo being reddish yellow. Headaches appear along with eyeball pain. Nausea and vomiting are manifestations of increased intraocular pressure. This is caused by activation of the vomiting center in the medulla due to triggering afferent input from pain receptors in the periphery. Bradycardia and sweating may occur as other vasovagal responses. Patients also sometimes complain of stomach cramps.(Yulia Puspita & Najwa, 2023).

Diagnosis

Sudden pain around the eyes and up to the head, can be accompanied by nausea and vomiting, red eyes, and blurred vision with sudden decreased visual acuity. There is a significant increase in eye pressure, more than 21mmHg, even reaching 50-80 mmHg, conjunctiva. hyperemic, the cornea is edematous and cloudy, the anterior chamber is shallow van Herick 0-1, the iris is difficult to assess because the cornea is cloudy, the pupil is middilated, not reactive to light, the pupil is oval/irregular in shape. Funduscopy examination could not be evaluated because the media was cloudy.

Treatment

1. Lower intraocular pressure immediately with medication and evaluate within 24 hours, with administration
*Carbonic anhydrase*oral 500 mg then 3-4 x 250 mg, pilocarpine 2% 4x1 drop, timolol 0.5% 2 x 1 drop, oral/infusion hyperosmotic if necessary, the dose of 50% oral glycerin is 1 – 3 mL/KgBW, while 20% IV mannitol is 2.5 – 7 mL/KgBW by administering 60 drops per minute if surgery is to be performed with an IOP > 30 mmHg
2. Topical steroids 6 x 1 drop are given to reduce inflammatory reactions and corneal edema
3. Laser/surgical peripheral iridectomy or iridoplasty is performed if the condition is calm (IOP drops and corneal edema decreases). If the IOP is unresponsive to medication, trabeculectomy is performed without or with an antifibrotic agent (Mitomycin C/5-fluorouracil).
4. Cataract extraction can be done when the eye condition has calmed down
5. For the fellow eye, a laser/surgical peripheral iridectomy was performed to prevent the same attack from occurring.
6. *Follow up* IOP evaluation, gonioscopy, Humphrey static campimetry and OCT/imaging.

Prognosis

The prognosis of acute glaucoma relies heavily on early detection. This situation must be treated immediately to minimize damage to the trabeculum, lens and optic nerve. This is also done to prevent the formation of posterior synechiae and anterior peripheral synechiae. If you don't get proper and fast treatment, blindness will occur in a short time. It is also necessary to examine the other eye to prevent the same occurrence.(Yulia Puspita & Najwa, 2023)

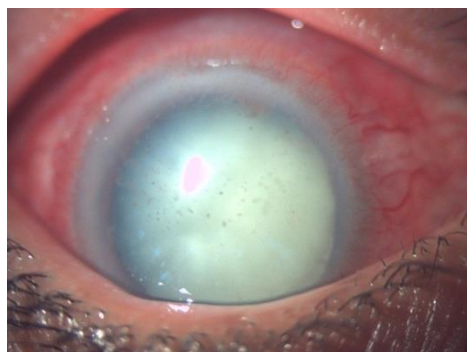

Figure 9. The anterior condition of the right eye shows a picture of Ephron gr III ciliary injection, corneal edema (+), microbullae (+), iris pigment (+), dilated round pupil. Cloudy lens.

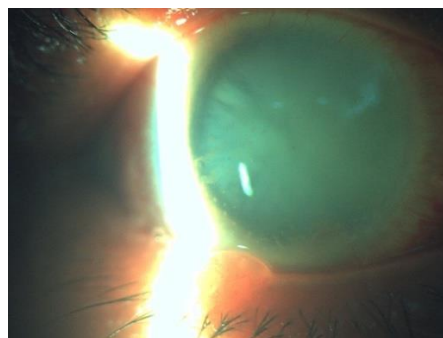


Figure 10. right eye: Anterior chamber H gr I-II

Case 5: Endophthalmitis

Case Scenario

A 71 year old woman came to the Emergency Department with complaints of blurry and red right eye. The patient had a history of phaco IOL OD cataract surgery 4 days previously. Right eye after surgery is still blurry, red (+), pain is denied. Treatment history is Ppred every hour, LFX every hour, MP 1x64mg, and Xitrol every hour. Generalist status examination was within normal limits. Ophthalmological examination showed VOD: 1/60 VOS: 0.8 pH remained. IOP OD: 5 mmHg, OS: 10mmHg. OS examination is within normal limits. Anterior segment examination of palpebral OD is relatively calm, ciliary injection (+), corneal edema (+), Descemet's fold (+), moderate COA with flare/cell +4/+4, hypopyon (+) 1mm, pharmacologically dilated pupil with light reflex down/down, iris within normal limits, PC IOL lens installed (+) good concentration, PCR (-), vitreous cells (+). The posterior segment of the funduscopy showed shadowy round papillae, vitreous haze, vitreous fibrosis and from ultrasound, vitreous opacity, DD inflammatory cells/vitreous fibrosis, double layer impression (+). The patient was diagnosed with Endophthalmitis OD + Pseudophakia OD then Vitreous tap + IVAB + aqueous tap + COA washout OD were performed.

Background

Endophthalmitis is an intraocular inflammatory condition involving the anterior and posterior segments of the eye, associated with bacterial or fungal infections. Often the retina or choroid is involved, sometimes accompanied by infectious scleritis or keratitis. In general, endophthalmitis can be classified into endogenous or exogenous endophthalmitis. Endogenous endophthalmitis is caused by hematogenous dissemination of bacteria or fungi originating from systemic (non-ocular) sources of infection, while exogenous endophthalmitis can be caused post-operatively (such as glaucoma or cataract surgery, pars plana vitrectomy, corneal transplantation, or exposed infected hectares), post injection, post-traumatic and

associated with microbial keratitis (Grzybowski, Turczynowska, Schwartz, Relhan, & Flynn, 2020),(Sen HN, 2022).

Diagnosis

Postoperative endophthalmitis is classified based on onset, namely acute onset (<6 weeks after surgery) and delayed onset (>6 weeks after surgery). Clinical manifestations of acute onset include intraocular inflammation, often with hypopyon, conjunctival hyperemia, and edema of the lids and cornea. Symptoms complained by patients include pain and blurriness and even loss of vision. The most common causative organisms found are *Staphylococcus* sp., *Staphylococcus aureus*, *Streptococcus* sp., and gram-negative organisms. Intraocular culture is required for monitoring which can be obtained via a needle tap to collect a vitreous specimen.(Sen HN, 2022) (Grzybowski et al., 2020).

Treatment

Management for endophthalmitis includes immediate vitreous tap and intravitreal antibiotic injection. Intravitreal antibiotic injection should always be given after obtaining a culture sample. The antibiotics commonly given are vancomycin and ceftazidime. The role of vitrectomy in cases of post-operative endophthalmitis is adjusted to the results of the Endophthalmitis Vitrectomy Study (EVS), which states that pars plana vitrectomy (PPV) is indicated in acute-onset post-operative patients (<6 weeks) with early light perception (LP) vision.(Sen HN, 2022),(Grzybowski et al., 2020) Additionally, in accordance with EVS, the use of systemic antibiotics may be considered in patients with severe signs, including panophthalmitis, early light perception (LP) vision, extensive hypopyon, or loss of fundus reflexes. The study results also found that cases of endophthalmitis with initial no light perception (NLP), panophthalmitis, or ecogenic causes did not receive intravitreal antibiotics but had a higher risk of enucleation/evisceration (Lugo Merly et al., 2022).

Prognosis

In general, cases of endophthalmitis have a poor prognosis, but postoperative infectious endophthalmitis is associated with a better visual prognosis compared with other etiologies. In addition, less virulent pathogens and intraoperative prophylaxis may contribute to a reduced need for enucleation/evisceration in cases of postoperative endophthalmitis. Factors found to improve the visual prognosis in cases of post-operative endophthalmitis include acute onset (within seven days after surgery) and routine post-operative follow-up with an eye specialist for earlier diagnosis and treatment.(Lugo Merly et al., 2022)

Picture

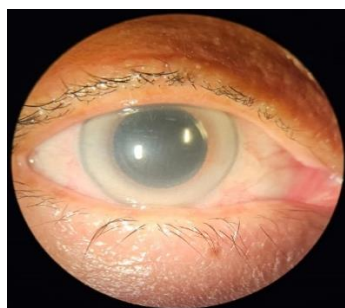

Figure 11. Anterior segment of the eye with ciliary injection, corneal edema, and hypopyon depicting endophthalmitis 4 days after cataract surgery

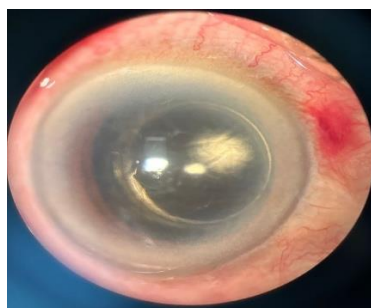

Figure 12. Eye condition after citreous tap + IVAB + aqueous tap + COA OD washout.

Case 6: Central Retinal Artery Occlusion

Case Scenario

A 78 year old man came to the Emergency Department with complaints of suddenly darkening in his right eye when he woke up from sleep, 2 hours before being admitted to the hospital. The patient denies any flashes of light, seeing rainbow-like shadows or the presence of floaters. The patient also denied any pain, red eyes, or discharge from the eyes. Denied history of double vision, trauma or eye surgery denied, patient has no history of wearing glasses, patient has history of uncontrolled hypertension and diabetes. Ophthalmological examination revealed VOD: 1/300 OS: 0.2 f2 PH 0.7. IOP OD: 9 mmHg, OS: 10 mmHg. Movement of the balls of both eyes is good in all directions, no pain. Examination of the anterior segment of the palpebral OD is relatively calm, the cornea is clear, fluorescent test(-), COA. Van Henrick grade III, round pupil Light reflex (+) RAPD grade III, clear lens. The posterior segment of the funduscopy of the right eye showed round papillae, clear boundaries, retinal flat, cherry red spot accompanied by retinal ischemia. The patient was diagnosed with OD central retinal artery occlusion, then OD paracentesis was performed.

Background

Central Retinal Artery Occlusion is an eye emergency. This occurs due to a sudden blockage of the central retinal artery, which results in retinal hypoperfusion, progressive cell damage, causing sudden loss of vision without any pain. Temporary loss of vision, also called amaurosis fugax, is caused by giant cell arteritis or embolism. on the retina. In one study, 66% of patients had visual acuity below 20/400 and 18% of patients had visual acuity above 20/40.2 Risk factors for this disease include hypertension, diabetes, obesity, abnormalities in blood fat, and atherosclerotic heart disease. In young patients with CRAO, the etiologic factors are often unclear. Brown et al reported that 30% of patients under 30 years of age who suffered from CRAO had a history of migraine headaches and autoimmune diseases (antiphospholipid antibody syndrome, sickle cell syndrome, and systemic lupus erythematosus/SLE). On examination of the posterior segment, images can be found. cherry-red spot on the macula, the retina becomes paler and edematous, and there is a patent cilioretinal artery in the area of the retina that appears normal. Permanent retinal damage occurs within 90 minutes of the onset of symptoms. Rapid diagnosis and early treatment must be carried out to remove the embolism or thrombus thereby preventing permanent retinal damage that ends in blindness.

Diagnosis

The diagnosis of central retinal artery occlusion is made based on the history, ophthalmological examination and supporting examinations. Through anamnesis, clinical signs will be found in the form of a sudden decrease in vision without pain, often when waking up in the morning because it is related to a decrease in retinal perfusion at night. In addition, patients may have a history of systemic diseases such as hypertension, history of heart disease, diabetes, obesity, smoking and blood lipid disorders. Through ophthalmological posterior segment examination, retina which is opaque and edematous, red reflexes from the choroidal blood vessels under the foveola contrast and stand out around the part of the neural retina which is in an opaque condition, giving rise to a cherry-red spot. Supporting examinations that can be carried out include fluorescein angiography to see the overall picture of the retinal blood vessels, in the acute phase shows delayed arterial filling. Optical Coherence Tomography (OCT) to determine the duration of ischemia. In the acute phase of retinal artery occlusion, OCT shows hyperreflectivity with thickening of the inner retina to include the outer plexiform layer. Color Doppler imaging is useful for viewing the retrobulbar circulation and detecting the classification of emboli in the lamina cribrosa.

Treatment

In acute situations central retinal occlusion must be performed immediately to maximize visual results. According to research, if retinal blood flow is restored within 90 minutes, then retinal damage has not occurred. Further partial recovery is possible if retinal blood flow is selected within 240 minutes, occlusion lasting more than 240 minutes will result in permanent retinal damage. 6 Treatment options that can be used include ocular massage, anterior chamber paracentesis, drugs to reduce pressure. intraocular, vasodilators (sublingual or transdermal nitroglycerin, oral isosorbide dinitrate, inhalation of a mixture of oxygen and carbon dioxide), and intra-arterial or intravenous thrombolysis. Anterior chamber paracentesis is indicated, especially if an embolus is seen in the optic disc.

Prognosis

If treated quickly and appropriately, visual acuity usually recovers to 20/50 or better in more than 80% of cases. Periodic examinations need to be carried out to see the possibility of complications. A frequent complication is iris neovascularization which causes neovascular glaucoma. Neovascularization of the iris, which has been reported to occur in 2.5% to 31.6% of patients. A recent study showed a prevalence of 18% with a mean onset of 8.5 weeks post-occlusion.

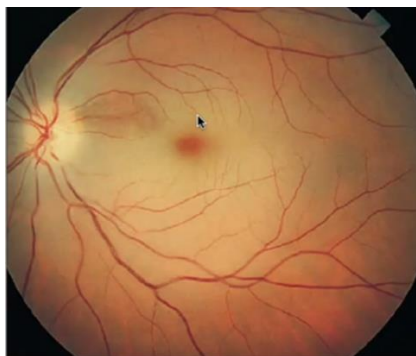

Figure 13. Condition of the posterior segment of the right eye, the retina looks pale, the macula is black accompanied by a cherry red spot.

Case 7: Corpus Alienum Oculi

Case Scenario

A 6 year old child came with his parents to the Emergency Department with complaints of difficulty opening his right eye, pain, and feeling like there was a foreign object stuck in it for 3 hours before entering the hospital. Previously, the patient was stabbed by a piece of fruit picking tool made from bamboo while playing with his younger brother. There was no history of eye cleaning, and no history of eye medication use in the patient. Basic visual examination of the right eye 0.5 pin hole is difficult. Intraocular pressure (IOP) examination of the right eye and examination of ball movement right eye is difficult because the patient is less cooperative. Examination of the anterior segment of the right eye using a flashlight and loupe revealed edema and blepharospasm in the superior and inferior eyelids. In the bulbar conjunctiva, it was found that there was a corpus alienum measuring around 7x5mm stuck in the inferior fornix, there was no active bleeding, the scleral laceration of the vulnus was difficult to assess. In the cornea of the right eye, corneal abrasion was found with positive fluorescence test results. On COA, VH gr III flare/cell +/- was obtained. Pupils are round with descending light reflex. Examination of the anterior segment of the left eye was within normal limits. The patient was then diagnosed with Corpus alienum a/r Inferior fornix OD + Susp. Open Globe Injury OD Type B gr 2 zone III Pupil Negative OD + Corneal abrasion OD + Susp. Vulnus Laceratum

Sclera OD. The patient was given preoperative management of Ringer Lactate (RL) infusion 12 drops/minute macrodrip, Cefotaxime 3x650mg intravenously, Paracetamol 4x250mg intravenously, administration of tetanus immunoglobulin 250 IU intramuscularly. The patient underwent exploration, corpus alienum extraction, and primary scleral OD hecting in the operating room with the help of general anesthesia.

Backgrounds

Corpus alienum oculi or foreign objects in the eye can be found in various age groups, backgrounds, gender and occupations. Cases of foreign bodies in the eye can occur through various mechanisms which can result in various possible final conditions for the patient's eyes. Foreign objects in the eye can be grouped into extra ocular and intra ocular. Groups of foreign bodies in the extra ocular area occur in the eyelids, sclera, conjunctiva and cornea. Meanwhile, the intra-ocular group occurs in the anterior chamber corner, iris, lens, vitreous, retina and intra-orbital areas. Usually foreign objects found in the eye area are dust fragments, sand, iron particles, wood particles, plants and insects.

Diagnosis

Foreign objects in the eye area can cause various complaints. The most common complaints are a feeling of burning, watering, difficulty opening the eyes or blepharospasm, blurred vision, and even blindness. In cases where patients experience penetrating injuries to the eyeball, additional investigations are required to ensure that there are no fragments of foreign objects remaining in the eyeball.

Treatment

Foreign objects in the eye are a type of eye emergency, so they must be removed immediately and ensure that there are no foreign objects remaining in the eye area. The procedure for dealing with foreign objects in the eye is to remove the foreign object according to the procedure and location of the foreign object. In the extra ocular area, patients are generally given local anesthesia and then the foreign object is removed using a small needle or cotton bud. In the intraocular foreign body group, the foreign body is removed along with exploration to ensure that there are no foreign bodies remaining in the eye. Procedures for removing foreign objects in the intra-ocular area are carried out in the operating room.

Prognosis

Cases of foreign bodies in the eye have varying prognoses depending on the speed and accuracy of treatment, the severity of the trauma, the material of the foreign body, and the location of the foreign body in the eye. Foreign objects located in the anterior part of the eyeball, parallel to the line of entry of light, will leave scars on the surface of the cornea and result in a sharp decrease in vision. Foreign objects which are types of organic material such as plants, rice, leaves, or tree debris, can increase the possibility of infection and risk causing endophthalmitis.

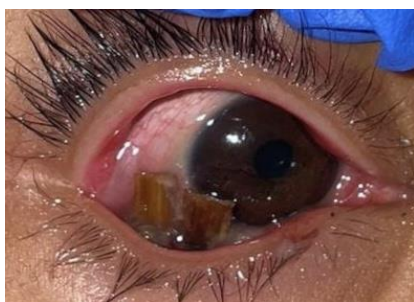

Figure 14. In the anterior segment of the eye, there are bamboo splinters embedded in the inferior fornix of the ocular right.

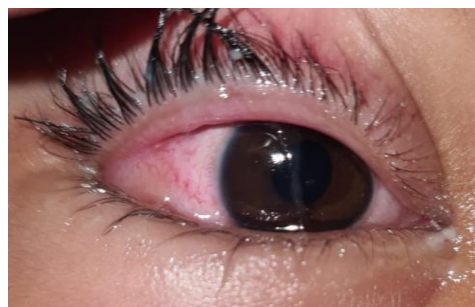

Figure 15. Condition of the anterior segment of the eye after exploration and removal of the foreign body.

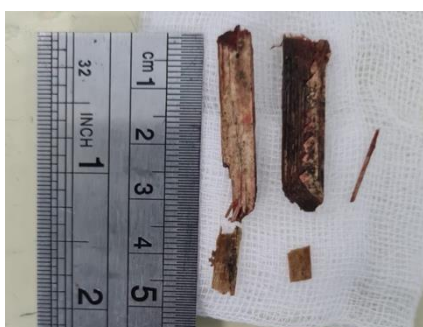

Figure 16. Condition of the anterior segment of the eye after exploration and removal of the foreign body.

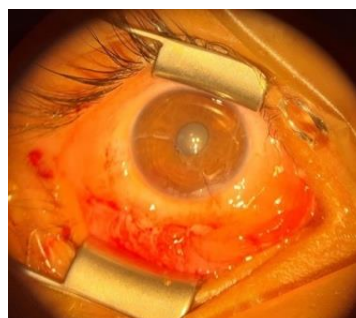


Figure 17. Foreign object in the form of a piece of bamboo that was successfully removed from right inferior ocular fornix.

Case 8: Mechanical Trauma

Case Scenario

A 10 year old child came to the Emergency Room accompanied by his parents with complaints of pain in his left eye, a lump and an injury after being hit by the end of a clothes hanger 9 hours before entering the hospital. The patient's parents said that at the time of the incident the patient was sleeping on a mattress next to which there was a metal clothes hanger, when the patient rolled around his left eye was pierced by the end of the clothes hanger but it did not stick. The eyes are not blurry and the bleeding has stopped. There was no fainting and no nausea and vomiting. After the incident, the patient could still go to school and then be taken to the PMN emergency room at Cicendo Eye Hospital. The patient is the third of three siblings, born normal, preterm, fully immunized, and growing according to age. The patient was compos mentis conscious, blood pressure 120/80 mmHg, pulse 82x/minute, respiration 20x/minute, temperature 36.3°C, and body weight 30 kg. Generalist status within normal limits. Ophthalmological status examination showed VOD 1.0, VOS 1.0, IOP OD 14 mmHg, IOP OS 7 mmHg. OD examination is within normal limits. Examination of the anterior segment of OS showed calm palpebra, bulbar conjunctiva showed ciliary injection and multiple vulnus laceratum a/r superotemporal measuring 1.7 x 0.5 cm at the top and 1 x 0.3 cm at the bottom at the base of the tenon, subconjunctival bleeding (+), cornea showed PEE and FT (+), CoA within normal limits, round pupils, light reflex +/+, clear lens. The posterior segment showed round papillae, clear boundaries, and clearly defined retina. Head x-ray examination showed normal results. The patient was diagnosed with Vulnus Laceratum Conjunctiva Bulbi OS a/r Superotemporal + Subconjunctival Bleeding OS + Corneal

Abrasion OS, then ATS and TT injections were carried out, exploring and hectating CB in the LA, and given eye drops Lyteers 6x OS, LFX 6x OS, and ointment mycetin 3x OS.

Background

Trauma to the eye is an emergency that can threaten vision. Eye trauma can occur due to mechanical and non-mechanical trauma. Mechanical trauma can occur due to blunt trauma, lamellar laceration, eyeball rupture, penetrating trauma, and foreign objects in the eyeball. Non-mechanical trauma consists of chemical trauma, radiation trauma and thermal trauma. Nearly 55 million eye injuries occur every year in the world and around 1.6 million of them result in blindness. The three most common clinical manifestations of eye trauma are foreign bodies (32.4%), lacerations (14.9%), and chemical trauma (10.4%).

Diagnosis

Mechanical trauma affecting the anterior segment can occur in the conjunctiva, cornea, sclera, iris, and even the lens. A detailed history including the time of the incident, the mechanism of the incident, evaluation of visual acuity, and a thorough eye examination to determine whether there are lacerations, perforations, or foreign bodies, as well as imaging techniques such as ultrasound and tomography need to be carried out to determine the severity of the trauma. Terminology for assessing specific criteria for eye trauma can use the Birmingham Eye Trauma Terminology (BETT).

Table 1.
Birmingham Eye Trauma Terminology (BETT)

Term	Definition/interpretation	Explanation
Eyewall	Sclera and cornea	Though technically the eyewall has three coats posterior to the limbus, for clinical and practical purposes, violation of only the most external structure is taken into consideration
Closed globe injury	No full-thickness wound of eyewall	
Open globe injury	Full-thickness wound of eyewall	
Contusion	No (full-thickness) wound	The injury results from direct energy delivery by the object (e.g) choroidal rupture or from the changes in the shape of the globe (e.g. angle recession)
Lamellar laceration	Partial-thickness wound of the eyewall	The wound of the eyewall is not through but into
Rupture	Full-thickness wound of the eyewall caused by a blunt object	Because the eye is filled with incompressible liquid, the impact results in momentary increase of the intraocular pressure. The eyeball eyelids at its weakest point (at the impact site or elsewhere; e.g an old cataract wound dehisces even though the impact occurred elsewhere). The actual wound is produced by an inside out mechanism
Laceration	Full-thickness wound of the eyewall caused by a sharp object	The wound occurs at the impact site by an outside in mechanism
Penetrating injury	Entrance wound	If more than one wound is present each must have been caused by a different agent
Intraocular foreign body	Retained foreign objects	Technically this is a penetrating injury but grouped separately because of different clinical implications
Perforating injury	Entrance and exit wounds	Both wounds are caused by the same agents

Source: Kuhn F.

This classification is used to equate perceptions of examination results obtained between doctors or other health workers in assessing and diagnosing mechanical eye trauma. When a

conjunctival laceration is diagnosed, it is necessary to know whether there is subconjunctival bleeding, foreign objects remaining, scleral lacerations, and the possibility of perforation of the eyeball. Subconjunctival hemorrhage that occurs due to mechanical trauma is the result of an accumulation of bleeding that occurs acutely and does not cause pain.

Treatment

Management of mechanical eye trauma depends on the results of the clinical examination and paying attention to the mechanism of the injury itself. The main goal of trauma management is to restore eye anatomy, optimize visual acuity, and minimize the risk of infection which will worsen the condition of mechanical eye trauma. The treatments that can be carried out consist of surgical and non-surgical. Conjunctival lacerations of more than 10 mm will heal in approximately 1 week, lacerations of 10 mm – 20 mm can be pressure patched for 24 hours with antibiotic ointment, while lacerations of greater than 20 mm require suturing and surgery. However, if the laceration is horizontal and interferes with the re-epithelialization process due to the blinking process, sutures can be performed. A combination of antibiotics and topical steroid eye medication or antibiotic eye drops with topical non-steroidal anti-inflammatory drugs can be given to speed up the healing process and avoid secondary infections. In subconjunctival hemorrhage, although there is no specific therapy, it can be recommended to use artificial tears, cold compresses, and limit heavy activities first. In patients with anterior chamber inflammation, cycloplegic eye drops can be added.

Prognosis

Mechanical trauma that occurs to the eye needs to be treated appropriately and quickly to save the anatomy of the eye and minimize visual disturbances that occur. The prognosis of mechanical trauma can be seen from the Ocular Trauma Score (OTS).

Table 2.
Ocular Trauma Score (OTS)

Ocular Trauma Score (OTS)						
Stage 1	Variable				Rough points	
A	Basic Vision					
	NLP				60	
	LP/HM				70	
	1/200-19/200				80	
	20/200-20/50				90	
	>20/40				100	
B	Luka perforasi				-14	
C	Ablasio retina				-11	
D	APD				-10	
E	Ruptur				-23	
F	Endophtalmitis				-17	
Stage 2 :		Add up the rough points : A+B+C+D+E+F				
Stage 3 :		Convert raw points to OTS scoring and final visual category calculation				
Rough number of points	OTS	NLP	LP/HM	1/200 – 19/200	20/200 – 20/50	>20/40
0-44	1	74%	15%	7%	3%	1%
45-65	2	27%	26%	18%	15%	15%
66-80	3	2%	11%	15%	31%	41%
81-91	4	1%	2%	3%	22%	73%
92-100	5	0%	1%	1%	5%	94%

Source from: Yan et al (30)

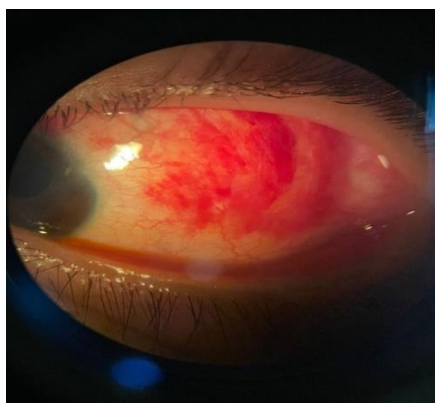

Figure 18. Condition of laceration before

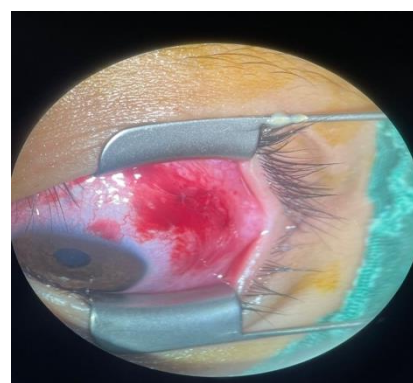


Figure 2. Laceration condition after

CONCLUSION

Management of cases of eye trauma depends on the severity. These include observation, therapy, surgery, and family support. Strategies and policies regarding eye emergencies involve related parties such as hospitals, eye clinics and other medical institutions. Community involvement in the form of outreach programs and campaigns to increase public awareness is needed as the front door in first handling.

REFERENCES

- Academy of Ophthalmology, A. (2019). *Glaucoma*. San Fransisco: American Academy of Ophthalmology.
- Braunger, B. M., Fuchshofer, R., & Tamm, E. R. (2015). The aqueous humor outflow pathways in glaucoma: A unifying concept of disease mechanisms and causative treatment. *Eur J Pharm Biopharm*, 95(Pt B), 173-181. doi:10.1016/j.ejpb.2015.04.029
- Brit Long, & Alex Koyfman. (2018). *Handbook of Emergency Ophthalmology*. Texas: Springer.
- Chen, J., Lan, J., Liu, D., Backman, L. J., Zhang, W., Zhou, Q., & Danielson, P. (2017). Ascorbic Acid Promotes the Stemness of Corneal Epithelial Stem/Progenitor Cells and Accelerates Epithelial Wound Healing in the Cornea. *Stem Cells Transl Med*, 6(5), 1356-1365. doi:10.1002/sctm.16-0441
- Fogt, J. S., Jones-Jordan, L. A., & Barr, J. T. (2018). Eye wash water flow direction study: an evaluation of the effectiveness of eye wash devices with opposite directional water flow. *Clin Ophthalmol*, 12, 669-676. doi:10.2147/opth.S157005
- Grzybowski, A., Turczynowska, M., Schwartz, S. G., Relhan, N., & Flynn, H. W., Jr. (2020). The Role of Systemic Antimicrobials in the Treatment of Endophthalmitis: A Review and an International Perspective. *Ophthalmol Ther*, 9(3), 485-498. doi:10.1007/s40123-020-00270-w
- Langan, R. C. (2022). Adult Eye Conditions: Ophthalmic Emergencies. *FP Essent*, 519, 29-32.
- Lugo Merly, A. N., Montalvo Toledo, L. A., Requejo, G. A., Meléndez, A., Álvarez, S., López, A., . . . Oliver, A. L. (2022). Risk Factors Leading to Enucleation or

- Evisceration in Infectious Endophthalmitis. *J Clin Med*, 11(11). doi:10.3390/jcm11113145
- Mayer, C. S., Reznicek, L., Baur, I. D., & Khoramnia, R. (2021). Open Globe Injuries: Classifications and Prognostic Factors for Functional Outcome. *Diagnostics (Basel)*, 11(10). doi:10.3390/diagnostics11101851
- Seanna Grob, & Kloeck, C. (2018). *Management of Open Globe Injuries* (1 ed.): Springer Cham.
- Sen HN, A. T., Burkholder BM, Dahr SS, Dodds EM, Leveque TK, et al.,. (2022). *Basic and Clinical Science Course, Section 09: Uveitis and Ocular Inflammation*. San Francisco: American Academy of Ophthalmology.
- Yulia Puspita, S., & Najwa, K. (2023). Primary Open Angle Glaucoma. *Jurnal Ilmiah Kedokteran dan Kesehatan*, 2(3). doi:10.55606/klinik.v2i3.1880
- Zhou, Y., DiSclafani, M., Jeang, L., & Shah, A. A. (2022). Open Globe Injuries: Review of Evaluation, Management, and Surgical Pearls. *Clin Ophthalmol*, 16, 2545-2559. doi:10.2147/opth.S372011

