



**TRACHEOSTOMY IN LARYNGEAL TUMOR PATIENTS WITH GRADE III UPPER AIRWAY OBSTRUCTION: A CASE REPORT**

**Irbah Nabila Aprilia\*, Fivien Fedriani**

Faculty of Medicine, Universitas Lampung, Jl. Prof. Dr. Ir. Sumantri Brojonegoro No.1, Gedong Meneng, Rajabasa, Bandar Lampung, Lampung 35141, Indonesia

[\\*irbahnabila99@gmail.com](mailto:*irbahnabila99@gmail.com)

**ABSTRACT**

The larynx is an organ that has a central role in coordinating the functions of the upper respiratory tract including respiration, speaking and swallowing. The larynx is divided into the supraglottis, glottis and subglottis. Laryngeal tumors are divided into 2 there are benign tumors where the most common is laryngeal papilloma and malignant tumors of the larynx which the most common is squamous cell carcinoma. Cases of laryngeal carcinoma often have complications of airway obstruction and require early and emergency treatment. Laryngeal obstruction requires special attention because the larynx is a narrow area of the upper airway. This study is a case report that observed patients with laryngeal tumors from before surgery to after surgery. The aim of this study was to determine the results of tracheostomy treatment in patients with laryngeal tumors. Airway obstruction can create shortness of breath due to airway obstruction which can be total or partial. This case report discusses Mr. S is 44 years old who has complained of shortness of breath since 3 days before entering the hospital. The patient also complained of a hoarse voice, sore throat, and a feeling of something being stuck since 7 months ago. The patient has also been an active smoker since he was 15 years old and has been drinking alcohol. The patient was finally diagnosed with well-differentiated squamous cell carcinoma of the larynx with OSNA grade III based on anamnesis, physical examination, and investigations. The patient underwent a tracheostomy to resolve airway obstruction and a microlaryngeal biopsy to confirm the diagnosis of carcinoma. After obtaining the results of the patient's anatomic pathology that the patient had laryngeal carcinoma, the action taken was a total laryngectomy.

Keywords: laryngeal tumor; tracheostomy; upper airway obstruction

|   |                                |                                    |
|---|--------------------------------|------------------------------------|
| <b>First Received</b><br>09 June 2023         | <b>Revised</b><br>16 July 2023 | <b>Accepted</b><br>30 July 2023    |
| <b>Final Proof Received</b><br>20 August 2023 |                                | <b>Published</b><br>31 August 2023 |

**How to cite (in APA style)**

Aprilia, I., & Fedriani, F. (2023). Tracheostomy in Laryngeal Tumor Patients with Grade III Upper Airway Obstruction: A Case Report. *Indonesian Journal of Global Health Research*, 5(3), 505-512. <https://doi.org/10.37287/ijghr.v5i3.2120>.

**INTRODUCTION**

The larynx is an organ that has a central role in coordinating the functions of the upper respiratory tract including respiration, speaking and swallowing. The larynx is divided into supraglottis, glottis and subglottis (Shah J et al., 2012) The larynx is the most common site for cancer of the upper aerodigestive. Head and neck cancer constitutes 5% of all malignancies in the human body and the incidence of malignant laryngeal tumors is around 1-2%. While research in Indonesia ranks third or fourth with an incidence of around 6-13% of malignancies in the ENT-KL field. (Shah J et al., 2012; Cheung NH, 2019) Laryngeal tumors are divided into 2, namely, benign tumors where the most common is laryngeal papilloma and malignant tumors of the larynx are squamous cell carcinoma. In 2011 there were an estimated 12,740 new cases of malignancy of the larynx in the United States and an estimated 3,560 deaths. Squamous cell carcinoma is the most common type of malignant tumor of the larynx, accounting for about 95% of all cases of laryngeal malignancy. The rest of the tumors

originate from the minor salivary glands, neuroepithelial, malignant tissue tumors and rarely arise from the cartilaginous bone of the larynx (Cheung NH, 2019)

The prevalence of tumors or cancer of the oral cavity and throat is 0.2%. This disease was found mostly in Central Java province and no cases were found in 5 provinces namely Jambi, West Sulawesi, North Maluku, West Papua and Papua. Risk factors associated with this disease are age, smoking/betel nut and oral hygiene. The incidence of tumors in the larynx is associated with smoking and alcohol consumption. In individuals who consume both the risk factors become synergy and the possibility of cancer is higher (Cahyadi, 2015) Malignant tumors of the larynx are still a problem in the field of ENT-KL. As an illustration abroad Ca larynx ranks fourth in the field of ENT-KL malignancies. In Indonesia, especially in the RSCM during the 2000-2005 period, 3,344 cases of malignant tumors were found in the head and neck area where the laryngeal cavities ranked second, namely around 213 cases (6.73%) after nasopharyngeal cancer 28.35% or around 948 cases. 6 There were 185 countries with an average of 1.0 people per 100,000 population die from laryngeal cancer (Bray F et al., 2018) The prognosis for a person with a laryngeal tumor is the best among other tumors in the aerodigestive tract if treated quickly and radically. Overall about 60% of patients survive longer which is about 5 years. More than 50% of patients survive 10 years after diagnosis of laryngeal cavities (Williamson J, 2012).

Cases of laryngeal carcinoma often have complications of airway obstruction and require early treatment and emergency. Upper airway obstruction is an emergency situation in the field of ENT specialist. Early diagnosis followed by prompt airway clearance can prevent cardiac arrest or irreversible brain damage occurring within minutes. Laryngeal obstruction requires special attention because the larynx is a narrow area of the upper airway. Airway obstruction can create shortness of breath due to airway obstruction which can be total or partial. In adults, the epiglottis is wider and the axis is parallel to the trachea, whereas in children, the epiglottis is omega-shaped and the axis angles away from the trachea. This condition will make it difficult when doing laryngoscopy. In terms of physiology, children are more prone to airway obstruction than adults. In patients with airway obstruction, the initial evaluation that must be done is the level of obstruction (Cheung NH, 2019).

Tracheostomy is a common procedure performed in critically ill patients who require prolonged mechanical ventilation for acute respiratory failure and airway problems. 1 Management of patients with upper airway obstruction can be treated by providing non-surgical measures, including oxygenation. The tracheostomy is carried out based on the condition of the SJNA gradation in the patient. Patients with gradations 1 and 2 were tracheostomy elective while those in gradations 3 and 4 were tracheostomy cito/urgently performed. If the patient suspects a tumor, a tracheostomy is done earlier without waiting for the degree of tightness to increase. Successful management must begin with a careful, thorough and rapid evaluation of the airway to identify a variety of causative factors (Shah J et al., 2012)

## **METHOD**

This research is case report. The subject of the study were male patient, aged 44 years with larungeal tumour who got tracheostomy according to his upper airway obstruction. Primary data was obtained from anamnesis, physical examination and supporting examination such as CT Scan, laryngoscopy, and biopsy. Evaluation and examination were carried out on January 31<sup>st</sup> to February 6<sup>th</sup>, 2022.

## RESULTS

Mr. S, 44 years old, came to the RSAM Polyclinic with complaints of shortness of breath since 3 days before entering the hospital. This complaint begins with a hoarse voice, sore throat and a feeling that something is stuck in the throat. Since 7 months ago. Initially the patient came to the hospital in the metro and was referred to an ENT specialist and was told he had an infection in his vocal cords and was given medication. However, after several months the complaints did not improve so the patient went to the ENT specialist again in August 2022 and was given more medicine but again the patient's complaints did not improve, the patient felt that his hoarseness was getting worse and the patient's voice was disappearing again until January 2023 the patient complained his throat hurt like being stabbed and his voice was getting hoarse so the patient decided to go to the hospital at the metro and finally the patient was referred to RSAM. The patient said he had a history of smoking since he was 15 years old by consuming 1 pack per day. The patient also consumed alcohol as a teenager. Complaints of coughing up blood were denied by the patient. No fever, runny nose, nose or ear complaints were found. The patient did not complain of eating and drinking disorders. There is a history of uncontrolled high blood pressure since 1 year ago. The patient had no history of diabetes mellitus or contact with TB patients. There were no complaints of swallowing pain and difficulty swallowing. Visual disturbances were also denied by the patient. There is no nosebleed or stuffiness. There were no lumps in the neck, armpits and groin.

On physical examination, awareness of compost mentis was found, BP : 150/100, HR : 126x/minute, RR : 28x/minute, T : 36.7 degrees Celsius, SpO2: 90%. On anterior thoracic examination, suprasternal retraction (+), intercostal retraction (+), and inspiratory stridor (+) were found. The results of laboratory investigations for complete blood counts showed leukocytosis, hyponatremia. The results of fiber optic laryngoscopy found that there was an irregular humped mass in the right ventricular plica and fixed vocal fold movement so that it was concluded that there was a supraglottic mass. The patient was given an injection of dexamethasone 1 amp/8 hours and planned to do a tracheostomy by cito. Follow-up examination on January 31 2023 found compost mentis awareness, BP : 150/90, HR : 100x/minute, RR : 28x/minute, T 26.6 degrees Celsius, SpO2 : 97% with nasal cannula 3L/minute, on examination Lungs showed inspiratory and expiratory stridor (+). The patient was diagnosed with a supraglottic mass and OSNA grade II so the latest management for the patient is an elective tracheostomy. Patients were given dexamethasone 1 ampoule/8 hours, ranitidine 1 ampoule/12 hours and Combivent nebu/8 hours. The patient was also planned to undergo TCM and microlaryngeal biopsy along with a tracheostomy.

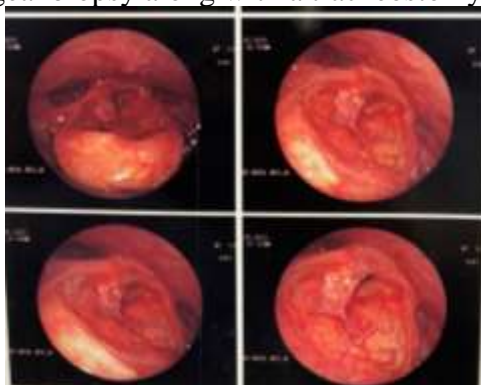


Figure 1. LFO results

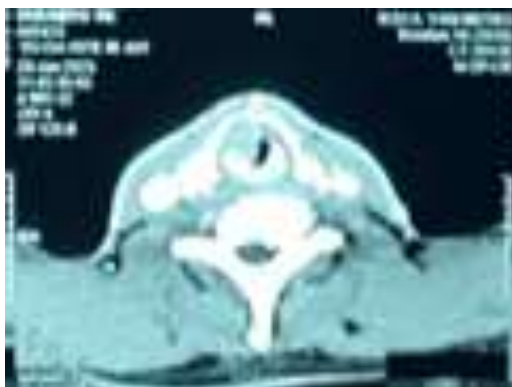

Figure 2. Axial Section CT Scan Results

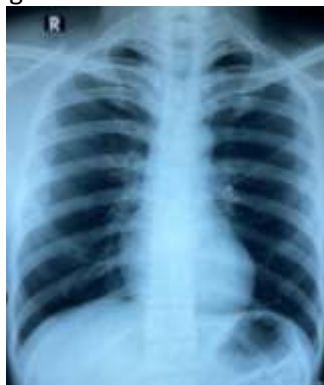

Figure 3. Thorax X-ray photo

On the results of anatomic pathology examination, the results of well-differentiated keratinized squamous cell carcinoma were found. The CT scan results showed a right supraglottic mass accompanied by dextra deep cervical lymphadenopathy with T2N1M0 stage. The results of a chest X-ray found pumo and cast within normal limits so that it can be concluded that there are no metastases to the lungs or mediastinum. The patient was diagnosed with laryngeal carcinoma. The management of this patient is to perform a total laryngectomy so that he needs to be referred to another hospital that provides more adequate facilities.

## DISCUSSION

The larynx is the central organ which plays a role in coordinating the functions of the aerodigestive tract in respiration, speech and swallowing. Laryngeal tumors are tumors that affect the larynx both in the supraglottis (cranial of the vocal folds), glottis, (vocal folds), and subglottis (caudal to the vocal folds) (Cheung NH, 2019) Most laryngeal tumors originate from the glottis, followed by the supraglottis and then the subglottis. Malignancy of the larynx is a frequent case that attacks the upper respiratory tract. The etiology is unknown, but several things are closely related, namely smoking and alcohol. One of the consequences of laryngeal tumors is laryngeal obstruction or upper airway obstruction which can result in death. Supraglottic and subglottic tumors have a characteristic complaint, namely hoarseness which usually occurs at the end of the symptoms so that patients usually do not go to the doctor, most of the new patients seek help after experiencing airway obstruction which requires emergency airway management Cahyadi, 2015).

In this case, the patient Mr. S was diagnosed with laryngeal tumor with OSNA grade III. This diagnosis is made on the basis of anamnesis, physical examination and supporting examinations. In the results of the anamnesis the patient complained of shortness of breath since 3 days of SMRS and this complaint was preceded by hoarseness, a feeling of lump and sore throat which had been felt since 7 months ago. Hoarseness or hoarseness is a symptom

caused by any condition that interferes with the normal phonation function of the larynx (Cahyadi, 2015; Maria, 2013). Complaints of hoarseness will usually persist in glottic tumors because they are right on the vocal cords, whereas in supraglottic and subglottic tumors these complaints are advanced complaints. Based on staging, the patient is included in stage III laryngeal carcinoma (T2N1M0) as can be seen from T2 (epiglottis) the tumor extends to the supraglottic area, the vocal cords are fixed (impaired mobility) (based on LFO results). This can be seen from the results of the CT SCAN with the appearance of a right supraglottic mass accompanied by deep cervical lymphadenopathy (N1) and no distant metastases (M0). Based on the results of a chest X-ray, no metastases were found, which is interpreted as M0. According to the AJCC in 2018 the stage in this patient was T2N1M0. Metastases are common in patients with large regional lymphadenopathy. The most common metastases are lung, bone and liver. But the farthest is to the KGB mediastinum (Romdhani, 2010; Hermani, 2000; Gourin CG, 2009).

From Williamjason's study (2012) it was found that 77.2% of patients with laryngeal tumors came with complaints of hoarseness. Patients also complain that there is a lump, sore throat like stabbing and coughing. In this group, the first symptoms were atypical and subjective, such as a feeling of discomfort, a feeling of something being stuck in the throat. Sore throat can vary from a scratching feeling to aching and sharp. Cough and hemoptysis are complaints that are commonly found in malignant glottic tumors and usually arise due to pressure on the hypopharynx accompanied by secretions flowing into the larynx, while hemoptysis often occurs in glottic tumors and supraglottic tumors. In malignant tumors of the larynx, the vocal cords fail to function properly due to vocal cord irregularities, occlusion or narrowing of the glottic cleft, large vocal cords, sharp edges of the vocal cords, attack of the vocal muscles, joints and cricoarytenoid ligaments, and sometimes attacks the nerves. The presence of a tumor in the vocal cords will interfere with the movement or vibration of the two vocal cords (Cheung NH, 2019).

The patient also complained of shortness of breath since the last 1 month before entering the hospital and worsened 3 days before entering the hospital. Shortness of breath or dyspnea is felt due to obstruction of the airway by a mass of tumors, accumulation of dirt or secretions, or by fixation of the vocal cords. Blockages that occur slowly can be compensated by the patient. Swallowing pain (odynophagia) indicates the presence of an advanced malignant tumor affecting the extra laryngeal structures (Maria, 2013) Diagnosis also needs a standard such as a penjunag examination in the form of a rigid or flexible endoscope so that it allows a comprehensive assessment to assess the primary tumor surface and vocal cord mobility. This examination is also important because it shows the location of origin of the primary lesion and the presence of local extension of the tumor to nearby structures or from one area to another. On the results of fiber optic laryngoscopy examination, it was found that there was an irregular humped mass on the surface of the right ventricular plica and there was fixation on the right vocal cord which caused the patient's voice to change and gradually disappear (Bray F *et al.*, 2018)

One of the most common causes of laryngeal cancer is smoking, where smokers have a higher risk than non-smokers. Excessive alcohol consumption is also a cause of laryngeal cancer by approximately 90% (Maria *et al.*, 2013). The patient was also an active smoker since he was 15 years old and drank alcohol since he was a teenager. This results in excessive exposure of cigarette smoke to the larynx and lungs. Exposure to incoming smoke causes the subglottis to become inflamed continuously until it finally enlarges and causes symptoms of shortness of breath. Several case studies have found an increased risk of laryngeal carcinoma of almost 2-4

times due to alcohol consumption (Williamson J, 2012). In Indonesia alone, according to RSCM data, it shows that laryngeal carcinoma is commonly found in people who smoke and the risk increases according to the number of cigarettes smoked. Koroulakis et al 2019 said that 70-90% of laryngeal carcinomas are smokers Vengatesh R *et al.*, 2017)

Malignant tumors of the larynx in the glottis are usually in the anterior 2/3 location, while the supraglottic area is most common in the epiglottis. The epiglottis area has a lot of lymph flow and leads to level II cervical lymph nodes, while the glottic area does not have two lymph channels. More than 95% of cases of malignant tumors of the larynx are squamous cell carcinomas. This is because the larynx is an organ covered with squamous epithelium which changes shape due to trauma exposure or due to carcinogenic stimuli, normal epithelial changes to malignant usually begin with leukoplakia, hyperplasia, non atypical keratosis, in situ carcinoma and microinvasive carcinoma. Apart from squamous cell carcinoma, other histopathological forms are verrucous ca, pseudosarcoma, and adenocarcinoma Sheahan P, 2009; Maharjan, 2010) On physical examination found suprasternal and intercostal retraction, stridor breath sounds on inspiration. This indicates the presence of stage III upper airway obstruction.<sup>10</sup>

Table 1.  
The criteria for airway obstruction are based on Jackson's criteria.

| Gradation | Criteria  |
|-----------|---|
| 1         | Mild suprasternal retractions, signs of fear (-)  |
| 2         | Suprasternal retraction (++) , epigastric (+), fear (+), hard to joke with                                      |
| 3         | Suprasternal retraction (+), clavicular (+), intercostal (+), epigastric (+), effort to inhale (+), fatigue (+) |
| 4         | Retraction (++), fear, cyanosis, refusal to eat/drink   |

The initial treatment is to perform an emergency tracheostomy for the patient to treat grade III upper airway obstruction caused by the tumor. However, when preparing for a tracheostomy, X-rays and laboratory results and given corticosteroids, the OSNA level of the patient decreased to stage II, which in the management of this case was not included in an emergency. It is enough to do an elective tracheostomy. Finally, the patient underwent a tracheostomy on 2 February 2023 and extirpation of the mass and microlaryngeal biopsy were performed.

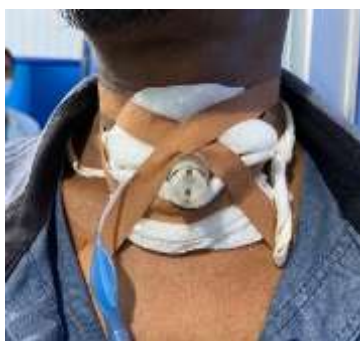

Figure 4. After installing the Tracheostomy Cannula

Tracheostomy is the gold standard in the treatment of upper airway obstruction, but tracheostomy has its own complications, both short and long term. Airway obstruction is a life-threatening emergency. Airway obstruction can be classified as partial or total and can occur from the larynx to the bronchioles. The etiology itself can be based on

inflammation/infection (acute laryngitis, acute epiglottitis, laryngeal angioedema, laryngeal diphtheria), neurological disorders (midline paralysis), foreign bodies (larynx-trachea-bronchi), tumors, trauma or congenital cholelithiasis in children ( laryngomalacia) Cheung NH, 2019). Surgery was the first choice in 57% of cases (259 patients), radiotherapy alone was performed in 124 patients (27%) and chemoradiation in 16% of cases (68 patients). 17 Patients with malignant laryngeal tumors had a lower recurrence rate than head and neck tumors. other. Glottic tumors have a better survival rate than subglottic and supraglottic tumors where regional spread is more common. Total laryngectomy is a radical surgical procedure in which the entire structure of the larynx is removed. This surgical procedure is used in the management of advanced laryngeal malignant tumors or advanced procedures. Previous partial laryngectomy and radiotherapy have failed. After a total laryngectomy, several methods are needed to produce sound, such as esophageal speech, the use of an artificial laryngeal, and TEP (transesophageal puncture) (Laendera et al., 2010)

## **CONCLUSION**

Laryngeal tumors are broadly divided into two types, namely benign and malignant tumors. Malignant tumor of the larynx is the most common tumor affecting the upper respiratory tract. The most common clinical symptoms of laryngeal tumors are shortness of breath and hoarseness. Management of malignant laryngeal tumors depends on the stage of the tumor at diagnosis. The diagnosis is made through anamnesis, physical examination, imaging examination, tissue biopsy and histopathological examination. Laryngeal tumors can cause laryngeal obstruction that causes death. The principle of managing upper airway obstruction caused by a tumor is to remove the cause of the blockage quickly and create a new airway that can guarantee ventilation (tracheostomy).

## **REFERENCES**

- Shah J, Patel SG, Singh B. Larynx and Trachea. (2012). Head and Neck Surgery and Oncology. Philadelphia: Elsevier Mosby. In: Shah J, Patel SG, Singh B, editors p. 811-992.
- Cheung NH, Napolitano LM. (2014). Tracheostomy: Epidemiology, Indications, Timing, Technique, and Outcomes. Dep Surg Univ Mich Ann Arbor Mich [Internet]. Vol. 3 | No. 3 | Desember 2019 | Jurnal Medical Profession (MedPro) 236 Jun;59. Available from: [rc.rcjournal.com/content/59/6/895.abstract](http://rc.rcjournal.com/content/59/6/895.abstract)
- Cahyadi I, Dinasti Permana A, Afriani Dewi Y. (2015). Karakteristik Penderita Karsinoma Laring di Departemen Ilmu Kesehatan Telinga Hidung Tenggorokan Bedah Kepala Leher Rumah Sakit dr. Hasan Sadikin Bandung Periode Januari 2013- juli 2015. Fak Kedokt Univ Padjadjaran [Internet]; Available from: [jurnal.unswagati.ac.id/index.php/tumed/articel/view/268](http://jurnal.unswagati.ac.id/index.php/tumed/articel/view/268)
- Maria Sirait A. (2013). Faktor Resiko Tumor/Kanker Rongga Mulut dan Tenggorokan di Indonesia (Analisis Risesdas 2007). Pus Teknol Interv Kesehat Masy Balitbangkes Kementerian Kesehat RI Jl Percetakan Negara No 29 Jkt Indones [Internet]. Sep;23, No 3. Available from: [ejournal.litbang.depkes.go.id](http://ejournal.litbang.depkes.go.id)
- Irfandy, D, Rahman SR. (2015). Diagnosis dan Penatalaksanaan Tumor Ganas Laring. J Kesehat Andalas [Internet]. 2015;4. Available from: <http://jurnal.fk.unand.ac.id>
- Hermani B, Abdurrachman B. (2015). Telinga Hidung Tenggorokan Kepala dan Leher. In: Telinga Hidung Tenggorokan kepala dan Leher. 4th ed. Jakarta. p. 176–80.

- Bray F, Ferlay J, Soerjomataram I, Siegel RL, Torre LA, Jemal A. (2018). Global Cancer Statistics. GLOBOCAN Estimates of Incidence and Mortality Worldwide for 36 Cancers in 185 Countries. *Glob Cancer Stat.* Desember;68:398.
- Rahman S. (2018). Diagnosis Dini Tumor Ganas Laring. *Pertem Ilm Nasioanal PIN Perhimpun Ahli THT-KL PERHATI-KL X* [Internet] ; Available from: <https://www.researchgate.net/publication/329359306>
- Williamson J, Biggs TC. (2012). Laryngeal cancer: an overview. *Univ Hosp Southampt Duncan Ingrams MA FRCS ORL-HNS Consult Head Neck Surg R Gwent Hosp Newport*; Available from: [www.trendsinurology.com](http://www.trendsinurology.com)
- Vengatesh R, Sanjeevan N, Nik Hassan NFH. (2017). Unusual cause acute airway obstruction. *Egypt J Ear Nose Throat Allied Sci.* Nov;18(3):303–5.
- Perhimpunan Dokter Spesialis Telinga Hidung Tenggorok Bedah Kepala Leher Indonesia. (2016). *Panduan Praktek Klinik, Tindakan, dan clinical pattway*; Perhimpunan Dokter Spesialis Telinga Hidung Tenggorok Bedah Kepala Leher Indonesia. Pengurus Pus Perhati-KL.
- Sheahan P, Ganly I, Evans PHR, Patel SG. (2009). Tumors of the larynx. In: Montgomery PQ, Evans PHR, Gullane PJ, editors. *Principles and practice of head and neck surgery and oncology*. Florida: Informa health care;. p. 257-90.
- Maharjan. (2010). Early complication of total laryngectomy: A Retrospective study. *SOL Nepal, Vol. 1 : 2.* p.17-18.
- Romdhoni AC. (2009). Aspek klinis dan diagnosis keganasan laring. Dalam naskah lengkap update in management of sinonasal and laryngeal cancer. Surabaya. P :109-19.
- Hermani, B. (2017). Laringektomi. Dalam naskah lengkap Simposium bedah kepala leher. Jakarta. 21-7.
- Edge SB *et al.* (2010). *AJCC Cancer Staging Manual, 7<sup>th</sup>ed.* New York, Springer, Chapter 5: Larynx, p. 57-67.
- Gourin CG *et al.* (2009). The Effect of Treatment on Survival in Patients with Advanced Laryngeal Carcinoma. *Laryngoscope*.
- Francis DO *et al.* (2009). Impact of surveillance on survival after laryngeal cancer in the Medicare population. *Laryngoscope*.
- Landra MA, Lundy DS, Sullivan PA. (2010). Dysphagia After Total Laryngectomy . Available from: <http://journals.asha.org/perspectives/terms.dtl>.